VERBIAGE AND MESSAGE FRAMING

In the Orthopedic Setting

Clinician Resource

Therapeutic Impact of Verbiage[1-4]

Psychological processes such as fear, patient expectations, and autonomy play an important role in recovery and outcomes throughout the rehabilitative process.

The following words have the potential to evoke

fear of movement and damage ■ negative emotions ■ beliefs of irreversible dysfunction

Words to Avoid		Consider Using Instead
Degeneration Wear and tear Bone on bone *"Your imaging shows multi-level degeneration in your spine"*	→	"Normal, age-related changes" *Consider use of visuals to enhance understanding*[5]
Stabilize Stability Instability *"This exercise will help to stabilize the neck"*	→	"Strengthen" "Improve muscular control" *Use of "stability" is appropriate in cases of true ligamentous instability where caution needs to be taken*
Compression Entrapment Impingement *"One of your nerves is being compressed near your spine"*	→	"Tight, but can be stretched" "Help things to move better" *Utilize words that indicate goals of treatment rather than focusing on pathoanatomy that may not elicit pain*
Medical/Anatomical Terms *lordosis, herniation, neurological, chronic, diagnostic, lesion, paresthesias*	→	normal curvature nervous system reduced feeling/sensation *audience dependent*

*Modifed from Stewart and Loftus, 2018[1]

Message Framing[6-9]

*how information is delivered

Research has revealed that benefit-framed messages encourage more active participation in less severe health circumstances[8-9]

Benefit-Framed

"**Participating** in PT for your rotator cuff tear will help to improve your functional **ability**, reduce pain, and help you to **self-manage** – likely **keeping** you from needing surgery"

Cost-Framed

"If you **don't** participate in PT, your pain and dysfunction will likely **persist**, leading you to **ongoing** care and increased **potential** for needing **surgery**"

Sarah McClellen, SPT

References

1. Stewart M, Loftus S. Sticks and Stones: The Impact of Language in Musculoskeletal Rehabilitation. J Orthop Sports Phys Ther. 2018;48(7):519-522. doi:10.2519/jospt.2018.0610
2. Chester R, Jerosch-Herold C, , Lewis J, , Shepstone L. and Psychological factors are associated with the outcome of physiotherapy for people with shoulder pain: a multicentre longitudinal cohort study. Br J Sports Med. 2018; 52: 269– 275. https://doi-org.libproxy.lib.unc.edu/10.1136/bjsports-2016-096084
3. Colloca, L., Klinger, R., Flor, H., & Bingel, U. (2013). Placebo analgesia: Psychological and neurobiological mechanisms. Pain, 154(4), 511–514. https://doi.org/10.1016/j.pain.2013.02.002.
4. Chua LK, Wulf G, Lewthwaite R. Choose your words wisely: Optimizing impacts on standardized performance testing. Gait Posture. 2020;79:210-216. doi:10.1016/j.gaitpost.2020.05.001
5. Paling, J. (2003). Strategies to help patients understand risks. BMJ, 327(7417), 745–748. https://doi.org/10.1136/bmj.327.7417.745.
6. Koban, L., Jepma, M., Geuter, S., & Wager, T. D. (2017). What's in a word? How instructions, suggestions, and social information change pain and emotion. Neuroscience & Biobehavioral Reviews, 81, 29–42.
7. Glare P, Fridman I, Ashton-James CE. Choose Your Words Wisely: The Impact of Message Framing on Patients' Responses to Treatment Advice. *Int Rev Neurobiol*. 2018;139:159-190. doi:10.1016/bs.irn.2018.07.020
8. Rothman AJ, Salovey P. Shaping perceptions to motivate healthy behavior: the role of message framing. Psychol Bull. 1997;121(1):3-19. doi:10.1037/0033-2909.121.1.3
9. Janke EA, Spring B, Weaver F. The effect of message framing on self-management of chronic pain: a new perspective on intervention?. Psychol Health. 2011;26(7):931-947. doi:10.1080/08870446.2010.514606

IMAGING CONSIDERATIONS

In the Orthopedic Setting

Clinician Resource

When is Imaging Indicated?

Presence of red flags[1-2]

history of cancer, signs of cauda equina, myelopathy, infection, or instability

Prior trauma[2-5]

Indicated by criteria such as Canadian C-Spine rules, Nexus, Ottowa Ankle, etc.

Failure of conservative treatment[1]

no change or worsening symptoms after 8 weeks

Pre-procedural information[1]

specific anatomical information for surgery, injection, etc

Effects of Imaging on Outcomes

In individuals with acute, work-related radicular and non-specific low back pain, obtaining early-MRI (≤30 days) led to significantly...

- Longer lengths of disability
- Increased medical costs

when compared to those who did not receive imaging.[6]

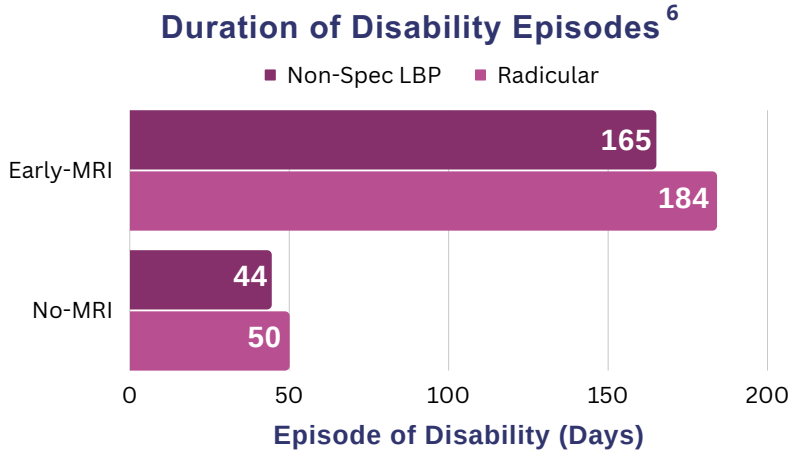

Heeding Caution with Imaging

This leads to a "medicalization" of many normal morphologies, which may lead patients to seek intensive, curative treatments, delaying functional restoration through rehabilitation.[1]

MRI and other imaging techniques have become highly specific. They can reveal anatomical abnormalities that do not correlate with symptoms and are commonly found in asymptomatic populations.[1,8,9-11]

Sarah McClellen, SPT

References

1. Flynn TW, Smith B, Chou R. Appropriate use of diagnostic imaging in low back pain: a reminder that unnecessary imaging may do as much harm as good. J Orthop Sports Phys Ther. 2011;41(11):838-846. doi:10.2519/jospt.2011.3618
2. Finucane L, Downie A, Mercer C, et al. International framework for red flags for potential serious spinal pathology. J Orthop Sports Phys Ther 2020;50(7):350–372. Epub 21 May 2020. doi:10.2519/jospt.2020.9971
3. Michaleff ZA, Maher CG, Verhagen AP, Rebbeck T, Lin CW. Accuracy of the Canadian C-spine rule and NEXUS to screen for clinically important cervical spine injury in patients following blunt trauma: a systematic review. CMAJ. 2012;184(16):E867-E876. doi:10.1503/cmaj.120675
4. Hoffman J, Mower W, Wolfson A, et al. Validity of a set of clinical criteria to rule out injury to the cervical spine in patients with blunt trauma. *N Engl J Med.* 2000; 343:94-99. doi:10.1056/NEJM200007133430203
5. Beckenkamp PR, Lin CC, Macaskill P, Michaleff ZA, Maher CG, Moseley AM. Diagnostic accuracy of the Ottawa Ankle and Midfoot Rules: a systematic review with meta-analysis. Br J Sports Med. 2017;51(6):504-510. doi:10.1136/bjsports-2016-096858
6. Webster BS, Bauer AZ, Choi Y, Cifuentes M, Pransky GS. Iatrogenic consequences of early magnetic resonance imaging in acute, work-related, disabling low back pain. Spine (Phila Pa 1976). 2013;38(22):1939-1946. doi:10.1097/BRS.0b013e3182a42eb6
7. Brinjikji W, Luetmer PH, Comstock B, et al. Systematic literature review of imaging features of spinal degeneration in asymptomatic populations. AJNR Am J Neuroradiol. 2015;36(4):811-816. doi:10.3174/ajnr.A4173
8. Barreto RPG, Braman JP, Ludewig PM, Ribeiro LP, Camargo PR. Bilateral magnetic resonance imaging findings in individuals with unilateral shoulder pain. J Shoulder Elbow Surg. 2019;28(9):1699-1706. doi:10.1016/j.jse.2019.04.001
9. Culvenor AG, Øiestad BE, Hart HF, Stefanik JJ, Guermazi A, Crossley KM. Prevalence of knee osteoarthritis features on magnetic resonance imaging in asymptomatic uninjured adults: a systematic review and meta-analysis. Br J Sports Med. 2019;53(20):1268-1278. doi:10.1136/bjsports-2018-099257
10. Teresi LM, Lufkin RB, Reicher MA, et al. Asymptomatic degenerative disk disease and spondylosis of the cervical spine: MR imaging. Radiology. 1987;164(1):83-88. doi:10.1148/radiology.164.1.3588931
11. Herzog R, Elgort DR, Flanders AE, et al. Variability in diagnostic error rates of 10 MRI centers performing lumbar spine MRI examinations on the same patient within a 3-week period. Spine J. 2017;17(4):554-561. doi:10.1016/j.spinee.2016.11.009

NORMATIVE FINDINGS

Spine Pathology

Clinician Resource

Anatomical abnormalities have been identified in both symptomatic and asymptomatic populations.[1-2] Providing education when necessary can help reframe how the patient views their pain and dysfunction.[3]

Age-Normative Data for Asymptomatic Individuals[1]

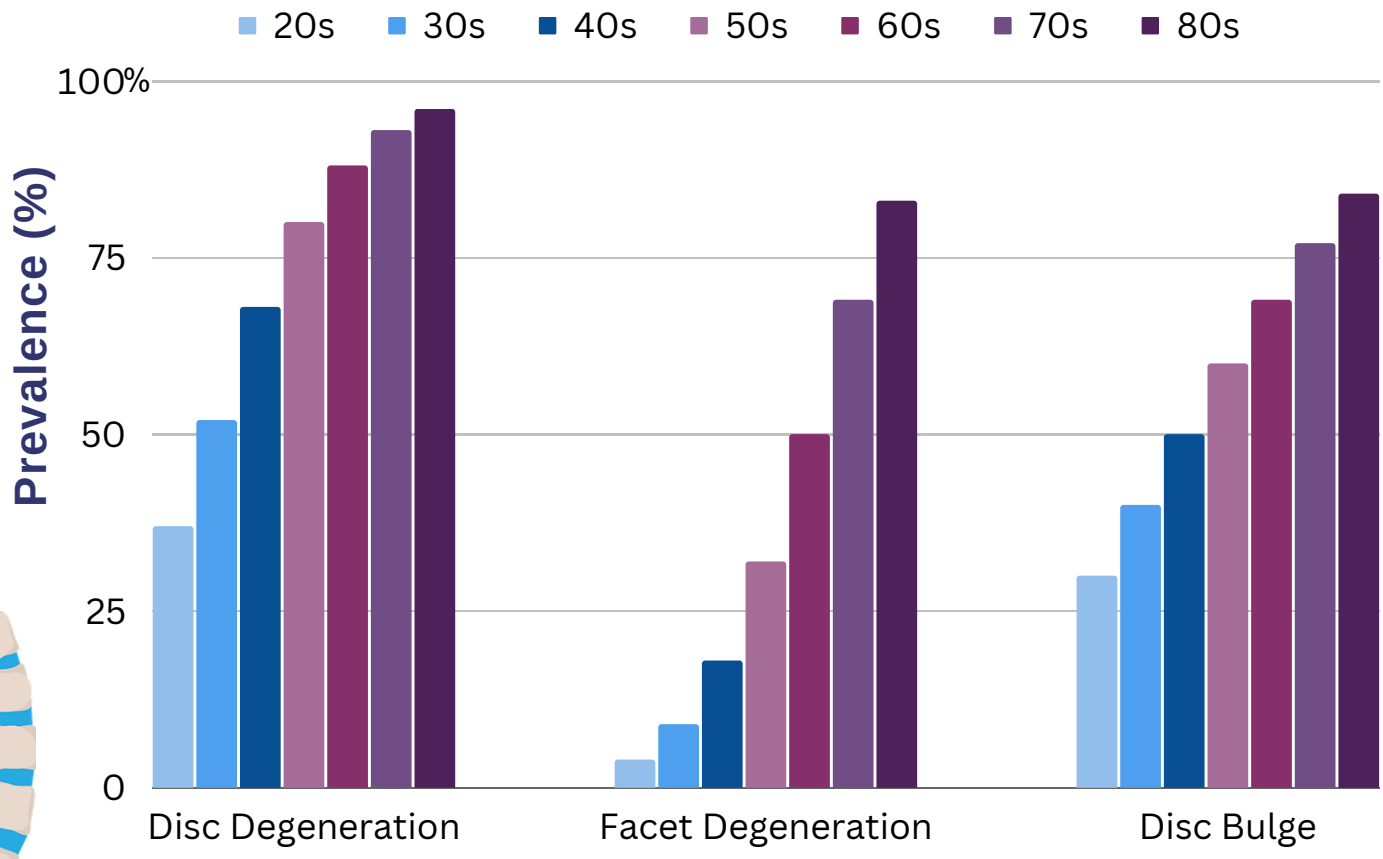

Symptomatic Populations

Presence of these findings should still be considered with caution and patients can progress even if imaging does not.[3]

In decreasing-odds order[2]

- Disc Bulge
- Spondylolysis
- Disc Extrusion
- Modic 1 changes
- Disc protrusion
- Disc Degeneration

Under the age of 50, certain imaging findings might be more prevalent in symptomatic individuals (compared to asymptomatic).[2]

⚠ Keep in mind: Symptomatic individuals may have more yellow flags and psychosocial risk factors.[6]

Sarah McClellen, SPT

NORMATIVE FINDINGS

Spine Pathology

Clinician Resource

Regression of Disc Pathology

High-quality literature review reveals that a large percentage of disc pathology will show partial, if not full, spontaneous regression within 1 year, and as early as 2 months.[8]

Regression might be lower in less severe pathologies due to the "normality" of these findings.[1-2,8]

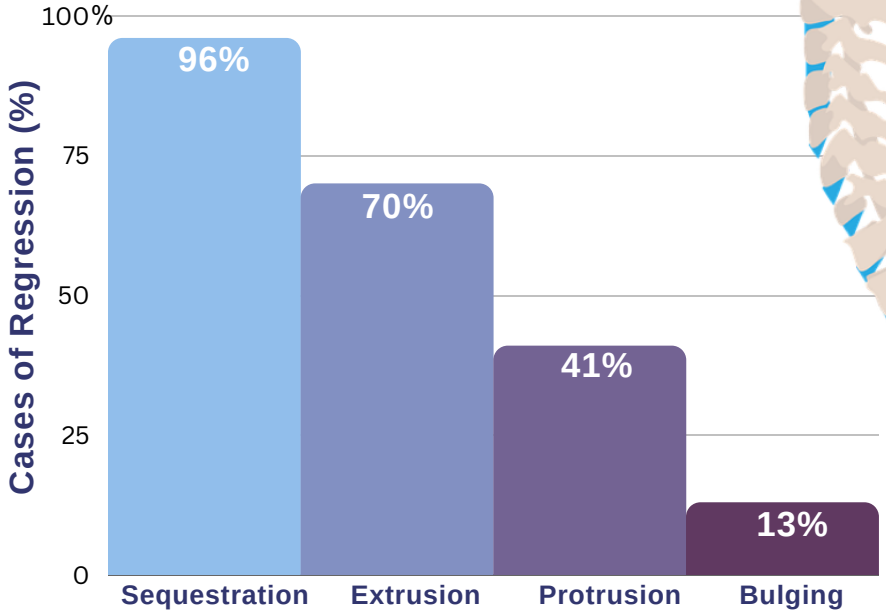

Presence of Disc Pathology by Decade in Asymptomatic Populations

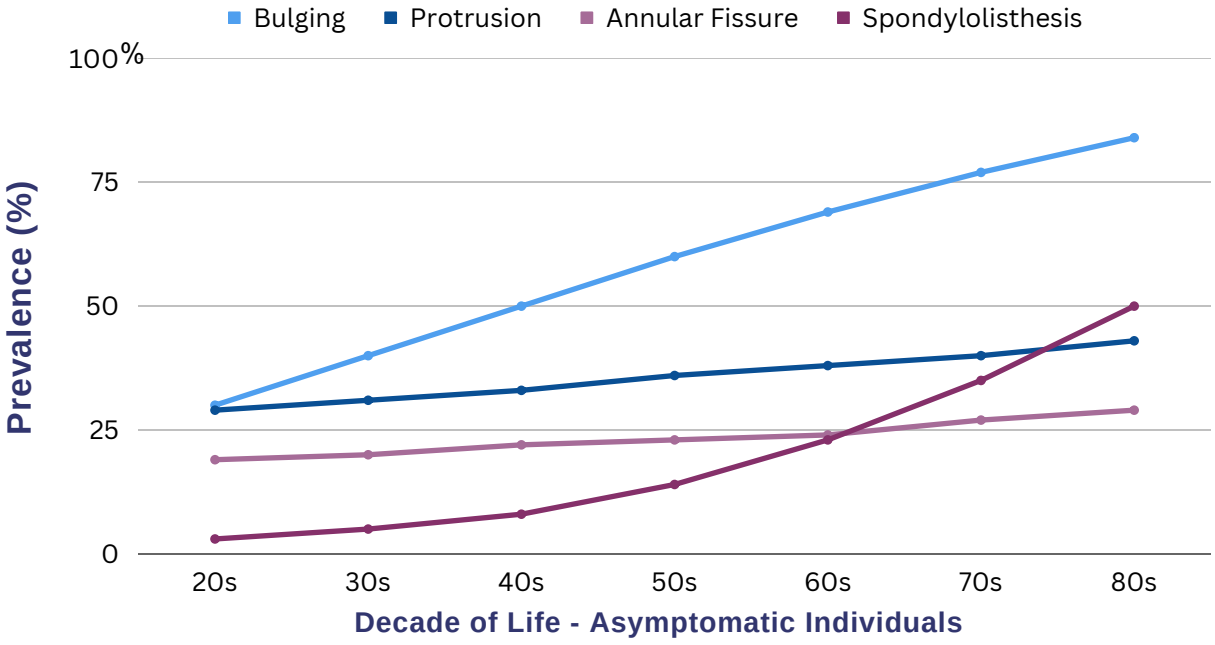

Clinical Implications

- The presence of asymptomatic anatomical abnormalities increases with age [1-2,4]
- Pathologic findings do not always indicate source of pain. Clinical outcomes can improve even without change in imaging.[1-3,7]
- Clinicians should consider the entire biopsychosocial being when educating about imaging and pain.[3,7,9-10]

Sarah McClellen, SPT

References

1. Brinjikji W, Luetmer PH, Comstock B, et al. Systematic literature review of imaging features of spinal degeneration in asymptomatic populations. *AJNR Am J Neuroradiol*. 2015;36(4):811-816. doi:10.3174/ajnr.A4173
2. Brinjikji W, Diehn FE, Jarvik JG, et al. MRI Findings of Disc Degeneration are More Prevalent in Adults with Low Back Pain than in Asymptomatic Controls: A Systematic Review and Meta-Analysis. *AJNR Am J Neuroradiol*. 2015;36(12):2394-2399. doi:10.3174/ajnr.A4498
3. Flynn TW, Smith B, Chou R. Appropriate use of diagnostic imaging in low back pain: a reminder that unnecessary imaging may do as much harm as good. *J Orthop Sports Phys Ther*. 2011;41(11):838-846. doi:10.2519/jospt.2011.3618
4. Zappalá M, Lightbourne S, Heneghan NR. The relationship between thoracic kyphosis and age, and normative values across age groups: a systematic review of healthy adults. *J Orthop Surg Res*. 2021;16(1):447. Published 2021 Jul 9. doi:10.1186/s13018-021-02592-2
5. Machino M, Ito K, Ando K, et al. Normative Magnetic Resonance Imaging Data of Age-Related Degenerative Changes in Cervical Disc Morphology. World Neurosurg. 2021;152:e502-e511. doi:10.1016/j.wneu.2021.05.123
6. Nieminen LK, Pyysalo LM, Kankaanpää MJ. Prognostic factors for pain chronicity in low back pain: a systematic review. *Pain Rep*. 2021;6(1):e919. Published 2021 Apr 1. doi:10.1097/PR9.0000000000000919
7. Agnus Tom A, Rajkumar E, John R, et al. Determinants of quality of life in individuals with chronic low back pain: a systematic review. *Health Psychol Behav Med*. 2022;10(1):124-144. Published 2022 Jan 5. doi:10.1080/21642850.2021.2022487
8. Chiu CC, Chuang TY, Chang KH, et al. The probability of spontaneous regression of lumbar herniated disc: a systematic review. *Clin Rehabil*. 2015;29(2):184-195. doi:10.1177/0269215514540919
9. Chester R, Jerosch-Herold C, Lewis J, et al. Psychological factors are associated with the outcome of physiotherapy for people with shoulder pain: a multicentre longitudinal cohort study. *Br J Sports Med*. 2018; 52: 269– 275. https://doi-org.libproxy.lib.unc.edu/10.1136/bjsports-2016-096084
10. Colloca L, Klinger R, Flor H, et al. Placebo analgesia: Psychological and neurobiological mechanisms. *Pain*, 2013. 154(4), 511–514. https://doi.org/10.1016/j.pain. 2013.02.002.

NORMATIVE FINDINGS

SHOULDER PATHOLOGY

Clinician Resource

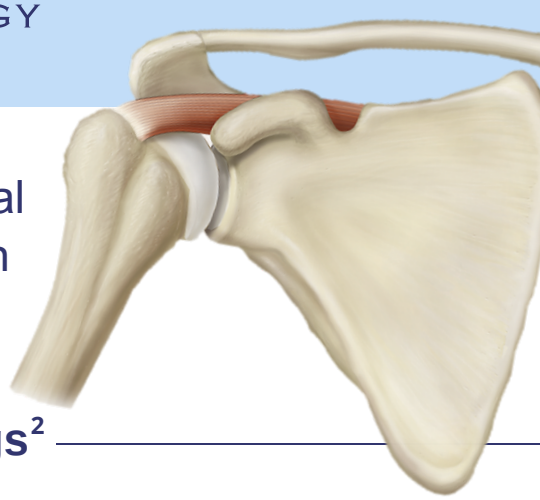

While imaging can identify the presence of abnormal pathology, findings do not necessarily correlate with clinical presentation.[1-6,9]

Symptomatic vs. Asymptomatic Imaging Findings[2]

*data is averaged from two imaging reviewers (Barreto, 2019)[2]

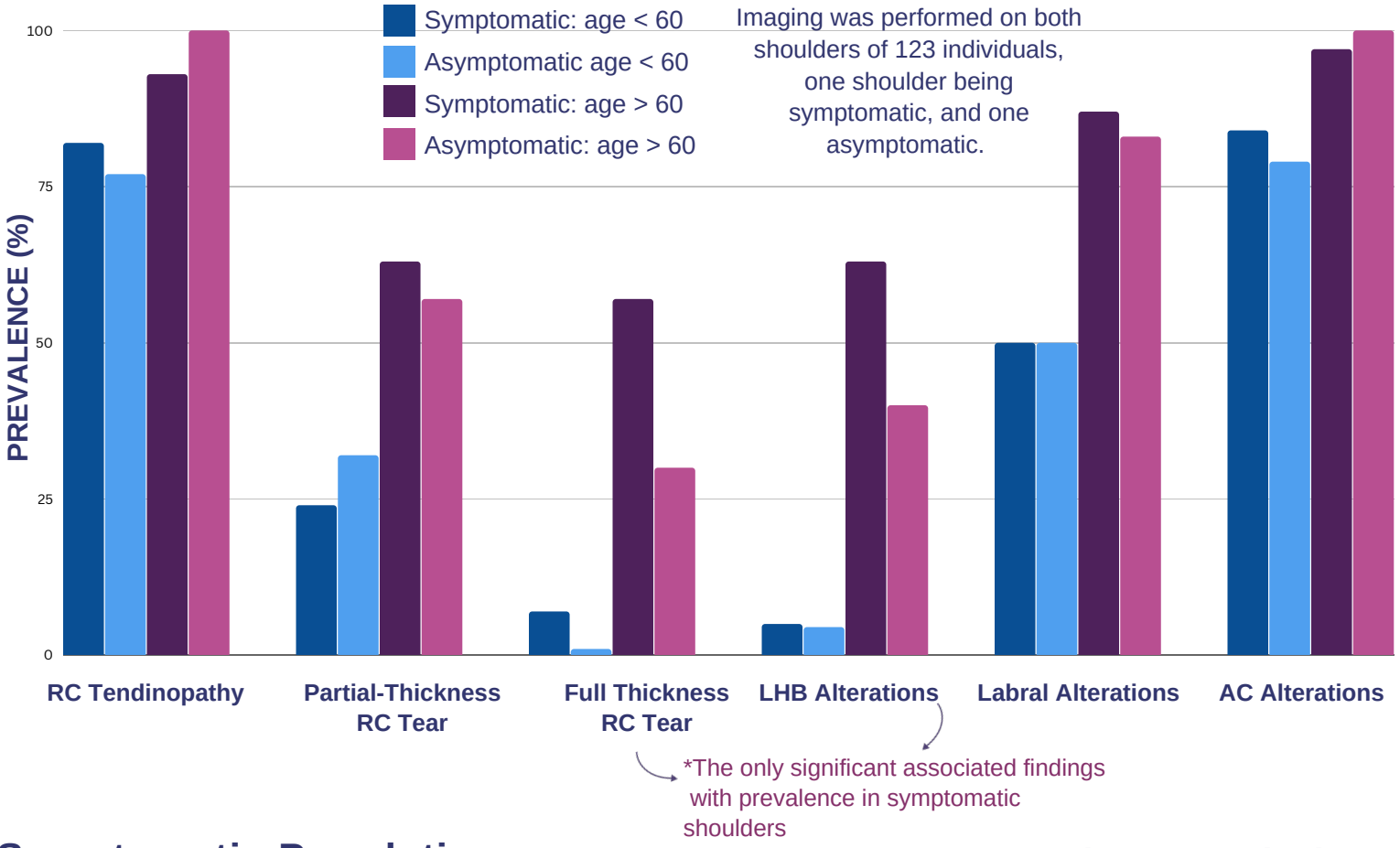

Symptomatic Populations

- Development of symptoms with a rotator cuff tear has a greater association with the *rate* of tear than size of tear.[1]
- Poorer long-term outcomes might be associated with the number of pathological findings in the shoulder.[9]

Active Populations

The prevalence of asymptomatic pathologies and exam findings might be even higher in athletic populations.[5,7,10]

Sport-dependent, scapular dyskinesias, tendinopathies, labral pathologies, and articular cartilage defects might be prevalent in 50-80%,[5,7] some of which match the findings above.[2]

Sarah McClellen, SPT

References

1. Mall NA, Kim HM, Keener JD, Steger-May K, Teefey SA, Middleton WD, Stobbs G, Yamaguchi K. Symptomatic progression of asymptomatic rotator cuff tears: a prospective study of clinical and sonographic variables. *J Bone Joint Surg Am*. 2010 11 17;92(16):2623–33. [PubMed: 21084574]
2. Barreto RPG, Braman JP, Ludewig PM, Ribeiro LP, Camargo PR. Bilateral magnetic resonance imaging findings in individuals with unilateral shoulder pain. *J Shoulder Elbow Surg.* 2019;28(9):1699-1706. doi:10.1016/j.jse.2019.04.001
3. Lawrence RL, Moutzouros V, Bey MJ. Asymptomatic Rotator Cuff Tears. *JBJS Rev*. 2019;7(6):e9. doi:10.2106/JBJS.RVW.18.00149
4. McLean JM, Awwad D, Lisle R, et al. An international, multicenter cohort study comparing 6 shoulder clinical scores in an asymptomatic population. *J Shoulder Elbow Surg.* 2018;27(2):306-314. doi:10.1016/j.jse.2017.08.016
5. Cooper JD, Seiter MN, Ruzbarsky JJ, et al. Shoulder Pathology on Magnetic Resonance Imaging in Asymptomatic Elite-Level Rock Climbers. *Orthop J Sports Med.* 2022;10(2):23259671211073137. Published 2022 Feb 11. doi:10.1177/23259671211073137
6. Tempelhof S, Rupp S, Seil R. Age-related prevalence of rotator cuff tears in asymptomatic shoulders. *J Shoulder Elbow Surg.* 1999;8(4):296-299. doi:10.1016/s1058-2746(99)90148-9
7. Burn MB, McCulloch PC, Lintner DM, et al. Prevalence of Scapular Dyskinesis in Overhead and Nonoverhead Athletes: A Systematic Review. *Orthop J Sports Med.* 2016;4(2):2325967115627608. Published 2016 Feb 17. doi:10.1177/2325967115627608
8. Teixeira DC, Alves L, Gutierres M. The role of scapular dyskinesis on rotator cuff tears: a narrative review of the current knowledge. *EFORT Open Rev*. 2021;6(10):932-940. Published 2021 Oct 19. doi:10.1302/2058-5241.6.210043
9. Kvalvaag E, Anvar M, Karlberg AC, et al. Shoulder MRI features with clinical correlations in subacromial pain syndrome: a cross-sectional and prognostic study. BMC Musculoskelet Disord. 2017;18(1):469. Published 2017 Nov 21. doi:10.1186/s12891-017-1827-3
10. Miniaci A, Mascia AT, Salonen DC, Becker EJ. Magnetic resonance imaging of the shoulder in asymptomatic professional baseball pitchers. Am J Sports Med. 2002;30(1):66–73.

References Compiled

References

Handout 1: Verbiage and Message Framing

1. Stewart M, Loftus S. Sticks and Stones: The Impact of Language in Musculoskeletal Rehabilitation. J Orthop Sports Phys Ther. 2018;48(7):519-522. doi:10.2519/jospt.2018.0610
2. Chester R, Jerosch-Herold C, , Lewis J, , Shepstone L. and Psychological factors are associated with the outcome of physiotherapy for people with shoulder pain: a multicentre longitudinal cohort study. Br J Sports Med. 2018; 52: 269– 275. https://doi-org.libproxy.lib.unc.edu/10.1136/bjsports-2016-096084
3. Colloca, L., Klinger, R., Flor, H., & Bingel, U. (2013). Placebo analgesia: Psychological and neurobiological mechanisms. Pain, 154(4), 511–514. https://doi.org/10.1016/j.pain.2013.02.002.
4. Chua LK, Wulf G, Lewthwaite R. Choose your words wisely: Optimizing impacts on standardized performance testing. Gait Posture. 2020;79:210-216. doi:10.1016/j.gaitpost.2020.05.001
5. Paling, J. (2003). Strategies to help patients understand risks. BMJ, 327(7417), 745–748. https://doi.org/10.1136/bmj.327.7417.745.
6. Koban, L., Jepma, M., Geuter, S., & Wager, T. D. (2017). What's in a word? How instructions, suggestions, and social information change pain and emotion. Neuroscience & Biobehavioral Reviews, 81, 29–42.
7. Glare P, Fridman I, Ashton-James CE. Choose Your Words Wisely: The Impact of Message Framing on Patients' Responses to Treatment Advice. Int Rev Neurobiol. 2018;139:159-190. doi:10.1016/bs.irn.2018.07.020
8. Rothman AJ, Salovey P. Shaping perceptions to motivate healthy behavior: the role of message framing. Psychol Bull. 1997;121(1):3-19. doi:10.1037/0033-2909.121.1.3
9. Janke EA, Spring B, Weaver F. The effect of message framing on self-management of chronic pain: a new perspective on intervention?. Psychol Health. 2011;26(7):931-947. doi:10.1080/08870446.2010.514606

References

Handout 2: Imaging Considerations

1. Flynn TW, Smith B, Chou R. Appropriate use of diagnostic imaging in low back pain: a reminder that unnecessary imaging may do as much harm as good. J Orthop Sports Phys Ther. 2011;41(11):838-846. doi:10.2519/jospt.2011.3618
2. Finucane L, Downie A, Mercer C, et al. International framework for red flags for potential serious spinal pathology. J Orthop Sports Phys Ther 2020;50(7):350–372. Epub 21 May 2020. doi:10.2519/jospt.2020.9971
3. Michaleff ZA, Maher CG, Verhagen AP, Rebbeck T, Lin CW. Accuracy of the Canadian C-spine rule and NEXUS to screen for clinically important cervical spine injury in patients following blunt trauma: a systematic review. CMAJ. 2012;184(16):E867-E876. doi:10.1503/cmaj.120675
4. Hoffman J, Mower W, Wolfson A, et al. Validity of a set of clinical criteria to rule out injury to the cervical spine in patients with blunt trauma. N Engl J Med. 2000; 343:94-99. doi:10.1056/NEJM200007133430203
5. Beckenkamp PR, Lin CC, Macaskill P, Michaleff ZA, Maher CG, Moseley AM. Diagnostic accuracy of the Ottawa Ankle and Midfoot Rules: a systematic review with meta-analysis. Br J Sports Med. 2017;51(6):504-510. doi:10.1136/bjsports-2016-096858
6. Webster BS, Bauer AZ, Choi Y, Cifuentes M, Pransky GS. Iatrogenic consequences of early magnetic resonance imaging in acute, work-related, disabling low back pain. Spine (Phila Pa 1976). 2013;38(22):1939-1946. doi:10.1097/BRS.0b013e3182a42eb6
7. Brinjikji W, Luetmer PH, Comstock B, et al. Systematic literature review of imaging features of spinal degeneration in asymptomatic populations. AJNR Am J Neuroradiol. 2015;36(4):811-816. doi:10.3174/ajnr.A4173
8. Barreto RPG, Braman JP, Ludewig PM, Ribeiro LP, Camargo PR. Bilateral magnetic resonance imaging findings in individuals with unilateral shoulder pain. J Shoulder Elbow Surg. 2019;28(9):1699-1706. doi:10.1016/j.jse.2019.04.001
9. Culvenor AG, Øiestad BE, Hart HF, Stefanik JJ, Guermazi A, Crossley KM. Prevalence of knee osteoarthritis features on magnetic resonance imaging in asymptomatic uninjured adults: a systematic review and meta-analysis. Br J Sports Med. 2019;53(20):1268-1278. doi:10.1136/bjsports-2018-099257
10. Teresi LM, Lufkin RB, Reicher MA, et al. Asymptomatic degenerative disk disease and spondylosis of the cervical spine: MR imaging. Radiology. 1987;164(1):83-88. doi:10.1148/radiology.164.1.3588931
11. Herzog R, Elgort DR, Flanders AE, et al. Variability in diagnostic error rates of 10 MRI centers performing lumbar spine MRI examinations on the same patient within a 3-week period. Spine J. 2017;17(4):554-561. doi:10.1016/j.spinee.2016.11.009

References

Handout 3: Normative Findings Spine Pathology

1. Brinjikji W, Luetmer PH, Comstock B, et al. Systematic literature review of imaging features of spinal degeneration in asymptomatic populations. AJNR Am J Neuroradiol. 2015;36(4):811-816. doi:10.3174/ajnr.A4173
2. Brinjikji W, Diehn FE, Jarvik JG, et al. MRI Findings of Disc Degeneration are More Prevalent in Adults with Low Back Pain than in Asymptomatic Controls: A Systematic Review and Meta-Analysis. AJNR Am J Neuroradiol. 2015;36(12):2394-2399. doi:10.3174/ajnr.A4498
3. Flynn TW, Smith B, Chou R. Appropriate use of diagnostic imaging in low back pain: a reminder that unnecessary imaging may do as much harm as good. J Orthop Sports Phys Ther. 2011;41(11):838-846. doi:10.2519/jospt.2011.3618
4. Zappalá M, Lightbourne S, Heneghan NR. The relationship between thoracic kyphosis and age, and normative values across age groups: a systematic review of healthy adults. J Orthop Surg Res. 2021;16(1):447. Published 2021 Jul 9. doi:10.1186/s13018-021-02592-2
5. Machino M, Ito K, Ando K, et al. Normative Magnetic Resonance Imaging Data of Age-Related Degenerative Changes in Cervical Disc Morphology. World Neurosurg. 2021;152:e502-e511. doi:10.1016/j.wneu.2021.05.123
6. Nieminen LK, Pyysalo LM, Kankaanpää MJ. Prognostic factors for pain chronicity in low back pain: a systematic review. Pain Rep. 2021;6(1):e919. Published 2021 Apr 1. doi:10.1097/PR9.0000000000000919
7. Agnus Tom A, Rajkumar E, John R, et al. Determinants of quality of life in individuals with chronic low back pain: a systematic review. Health Psychol Behav Med. 2022;10(1):124-144. Published 2022 Jan 5. doi:10.1080/21642850.2021.2022487
8. Chiu CC, Chuang TY, Chang KH, et al. The probability of spontaneous regression of lumbar herniated disc: a systematic review. Clin Rehabil. 2015;29(2):184-195. doi:10.1177/0269215514540919
9. Chester R, Jerosch-Herold C, Lewis J, et al. Psychological factors are associated with the outcome of physiotherapy for people with shoulder pain: a multicentre longitudinal cohort study. Br J Sports Med. 2018; 52: 269– 275. https://doi-org.libproxy.lib.unc.edu/10.1136/bjsports-2016-096084
10. Colloca L, Klinger R, Flor H, et al. Placebo analgesia: Psychological and neurobiological mechanisms. Pain, 2013. 154(4), 511–514. https://doi.org/10.1016/j.pain. 2013.02.002.

References

Handout 4: Normative Findings Shoulder Pathology

1. Mall NA, Kim HM, Keener JD, Steger-May K, Teefey SA, Middleton WD, Stobbs G, Yamaguchi K. Symptomatic progression of asymptomatic rotator cuff tears: a prospective study of clinical and sonographic variables. J Bone Joint Surg Am. 2010 11 17;92(16):2623–33. [PubMed: 21084574]
2. Barreto RPG, Braman JP, Ludewig PM, Ribeiro LP, Camargo PR. Bilateral magnetic resonance imaging findings in individuals with unilateral shoulder pain. J Shoulder Elbow Surg. 2019;28(9):1699-1706. doi:10.1016/j.jse.2019.04.001
3. Lawrence RL, Moutzouros V, Bey MJ. Asymptomatic Rotator Cuff Tears. JBJS Rev. 2019;7(6):e9. doi:10.2106/JBJS.RVW.18.00149
4. McLean JM, Awwad D, Lisle R, et al. An international, multicenter cohort study comparing 6 shoulder clinical scores in an asymptomatic population. J Shoulder Elbow Surg. 2018;27(2):306-314. doi:10.1016/j.jse.2017.08.016
5. Cooper JD, Seiter MN, Ruzbarsky JJ, et al. Shoulder Pathology on Magnetic Resonance Imaging in Asymptomatic Elite-Level Rock Climbers. Orthop J Sports Med. 2022;10(2):23259671211073137. Published 2022 Feb 11. doi:10.1177/23259671211073137
6. Tempelhof S, Rupp S, Seil R. Age-related prevalence of rotator cuff tears in asymptomatic shoulders. J Shoulder Elbow Surg. 1999;8(4):296-299. doi:10.1016/s1058-2746(99)90148-9
7. Burn MB, McCulloch PC, Lintner DM, et al. Prevalence of Scapular Dyskinesis in Overhead and Nonoverhead Athletes: A Systematic Review. Orthop J Sports Med. 2016;4(2):2325967115627608. Published 2016 Feb 17. doi:10.1177/2325967115627608
8. Teixeira DC, Alves L, Gutierres M. The role of scapular dyskinesis on rotator cuff tears: a narrative review of the current knowledge. EFORT Open Rev. 2021;6(10):932-940. Published 2021 Oct 19. doi:10.1302/2058-5241.6.210043
9. Kvalvaag E, Anvar M, Karlberg AC, et al. Shoulder MRI features with clinical correlations in subacromial pain syndrome: a cross-sectional and prognostic study. BMC Musculoskelet Disord. 2017;18(1):469. Published 2017 Nov 21. doi:10.1186/s12891-017-1827-3
10. Miniaci A, Mascia AT, Salonen DC, Becker EJ. Magnetic resonance imaging of the shoulder in asymptomatic professional baseball pitchers. Am J Sports Med. 2002;30(1):66–73.